



Parotid Gland Primary Amelanotic Malignant Melanoma

Primer Parotis Bezi Amelanotik Malign Melanoması

Eltaf Ayça Özbal Koç¹, Çiğdem Kalaycık Ertugay², Şemsi Altaner³

Amelanotic malignant melanoma (AMM) represents only 2%–8% of all malignant melanomas, and primary AMM of the parotid gland is very rarely diagnosed. This is the second case of primary AMM of the parotid gland in the literature. The aim of this report is to discuss our case and this rare entity. The detection of AMM is very complex because the pathology results can be confused with those for inflammatory processes and benign and malignant tumors. Immunohistochemical analysis of S100 protein and human melanoma black 45 (HMB45) analysis provides guidance in the differential diagnosis of AMM. In this report, we present a rapidly growing amelanotic malignant melanoma in the parotid gland. Examination of the patient and radiological studies showed no other lesions.

Keywords: Melanoma, parotid gland, tumor

Tüm malign melanomların sadece %2-8'i amelanotik malign melanom (AMM)'dur ve parotis bezinin AMM'si çok daha nadir bulunmaktadır. Bu olgu literatürdeki ikinci primer parotis bezi AMM'sidir. Bu yazıdaki amacımız bizim olgumuzu ve bu nadir hastalığı tartışmaktır. AMM'nin saptanması oldukça karmaşıktır çünkü patolojik çalışmalarda inflamatuvar süreç, benign ve malign tümör ayırt edilemeyebilir. S-100 protein and Human Melanoma Black 45 (HMB45) immünohistokimyasal analizi ayırıcı tanıda kılavuzluk sağlamaktadır. Bu yazıda parotis bezinde hızlı gelişen bir amelanotik malign melanomdan bahsedilmektedir. Hastanın muayenesi ve radyolojik incelemeleri sonrası herhangi başka bir lezyon gözlenmemiştir.

Anahtar Kelimeler: Melanom, parotis bezi, tümör

Introduction

Primary malignant melanomas (MMs) of the parotid gland are extremely rare. Only a few cases have been published in the literature; also, only one report has been published regarding a primary amelanotic malignant melanoma (AMM) of the parotid gland. AMM is an extremely rare tumor, and immunohistochemical analysis is needed to differentiate the diagnosis.

In this report, we present an AMM in the parotid gland, with no other primary lesions detected.

Case Report

An 80-year-old man presented to our clinic in December 2013 with a very large, painless, round, hard, fixed mass in the right parotid region that had been present for five months and had recently increased rapidly in size, accompanied by bleeding and a bad smell (Figure 1). Informed consent was obtained from the patient.

Four months previously, the patient had presented to another clinic with a painless mass in the right parotid region. There was no skin lesion at that time. A fine needle biopsy was performed. The pathology results indicated that the mass was a malignant tumor, and the surgeon suggested total parotidectomy; however, the patient was afraid of surgery and did not seek medical attention again until the mass started to bleed. Physical examination revealed a hard, bleeding, malignant mass which was attached to the underlying soft tissue.

Cervicofacial magnetic resonance imaging (MRI) showed a parotid mass measuring 82 × 43 × 34 mm with an undefined boundary. Also, the MRI showed pathological cervical nodes, the largest of which was measured to be 16 × 12 mm (Figure 1).

There was no functional impairment of the facial nerve.

The patient's laboratory results were normal. Subsequently, the patient underwent an incisional biopsy. Histopathological examination of the specimen fixed in buffered formalin along with immunohistochemical analysis confirmed the lesion to be an AMM. Microscopically, there was no evidence of a lymph node structure in the main tumor. The melanocytes

¹Department of Otorhinolaryngology, Başkent University Istanbul Hospital, İstanbul, Türkiye
²Clinic of Otorhinolaryngology, Haydarpaşa Numune Training and Research Hospital, İstanbul, Türkiye
³Department of Pathology, Başkent University Istanbul Hospital, İstanbul, Türkiye

Address for Correspondence

Yazışma Adresi:

Çiğdem Kalaycık Ertugay
E-mail: ckalaycik@gmail.com

Received/Geliş Tarihi:
13.11.2015

Accepted/Kabul Tarihi:
24.02.2016

© Copyright 2016 by Available online at
www.istanbulmedicaljournal.org

© Telif Hakkı 2016 Makale metnine
www.istanbultipdergisi.org web sayfasından
ulaşılabilir.

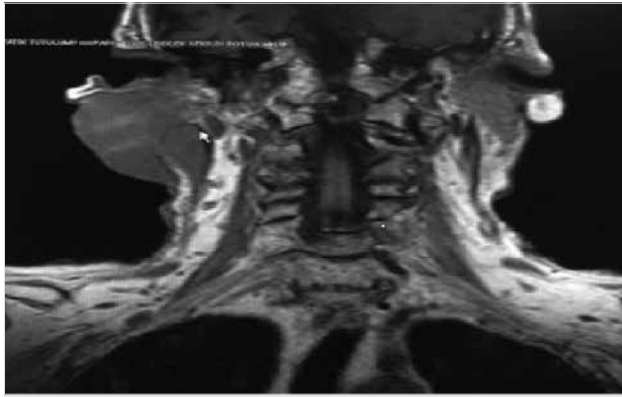


Figure 1. MRI showing a parotid mass measuring 82 × 43 × 34 mm
MRI: magnetic resonance imaging

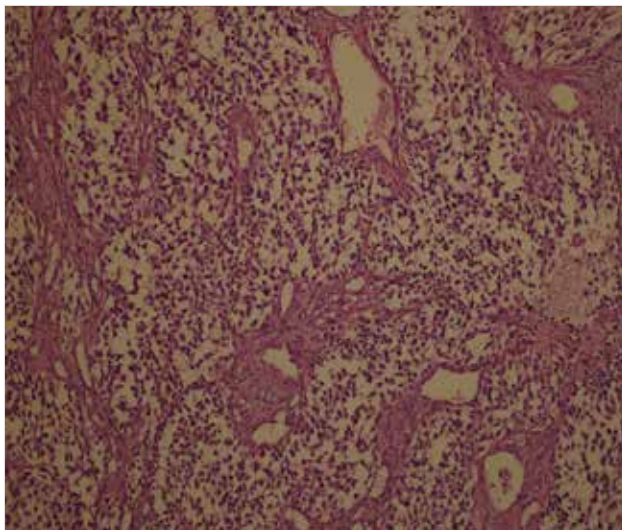


Figure 2. AMM cell groups with enlarged hyperchromatic nuclei and prominent nucleoli (haematoxylin and eosin stain × 100)
AMM: amelanotic malignant melanoma

formed groups and invaded the parotid tissue. The tumor cells had enlarged hyperchromatic nuclei with prominent nucleoli (Figure 2).

Immunohistochemical expression of S100 protein and human melanoma black 45 (HMB45) analysis gave positive results, while expression of cytokeratin (CK-10) was positive in some areas. Epithelial membrane antigen (EMA), CK, actin, and CEA tests were negative. From these findings, AMM was diagnosed.

Investigations to find other melanomatous lesions included careful physical examination, dermatological and ophthalmological examinations, gastrointestinal endoscopy, abdominal ultrasound, and cranial MRI. No abnormalities were found.

Positron emission tomography (PET) was then performed, and no other suspicious lesions were detected.

The patient declined surgery and was referred to an oncology clinic. He was treated with definitive irradiation (100 Gy) 37 times. Although the patient was completely cured, he developed right facial paralysis during the last three irradiation sessions.

Discussion

MMs of the head and neck are generally observed on the facial skin, with the cheeks being the most commonly affected area (1). While cutaneous MMs have a somewhat higher incidence among women than men, the incidence of head and neck melanomas is nearly two times greater among men. Compared to other types of melanoma, head and neck melanomas are also relatively more prevalent in older age groups (2).

Most MMs that are observed in the parotid gland are associated with metastases originating from primary cutaneous melanomas located on the head. These metastases generally reach the parotid gland through its surrounding lymph nodes (3).

It is very rare for MMs to originate directly from the parotid gland itself, and only a few cases of MMs primary to the parotid glands have been previously reported (4-6). These findings of primary MMs of the parotid gland were initially considered to be puzzling because the means and mechanisms through which melanocytes became localized in the parotid glands were unclear. Confusion regarding the origins of primary MMs of the parotid gland continued until Takeda (7) identified melanocytes for the first time within the interlobular ducts of the parotid gland during an autopsy.

In a report published in 1961, Greene and Bernier (8) suggested that these melanocytes could be possibly associated with melanoblasts that became incorporated into the parotid glands during embryonic development at the stage when oral epithelial cells first extended into the underlying mesenchyme to form salivary ducts and tissues. They supported their claim with evidence that certain cells from healthy parotid glands also contain melanin, as demonstrated by positive 3,4-dihydroxy-L-phenylalanine (L-DOPA) test results.

In a report published in 1997, Takeda (7) was the first to describe the identification of melanocytes in the parotid gland ducts during the autopsy of a male subject. In a manner similar to Greene and Bernier, Takeda rationalized the presence of melanocytes based on the prenatal/embryonic development of the salivary glands, noting that these glands are formed by cords of embryonic epithelial cells from the oral mucosa that proliferate towards the mesenchyme. While extending into the mesenchyme, these epithelial cells form extensive branches that later develop into the salivary ducts (and associated secretory system) through canalization. Takeda suggested that, as a consequence of this development process, melanocytes from the embryonic epithelium of the oral mucosa could be potentially carried into the mesenchyme and thus become incorporated into salivary glands, such as the parotid gland. Nevertheless, instances of melanocytes becoming part of the salivary glands are believed to be exceptionally rare. For example, among the parotid, submandibular, and sublingual glands Takeda examined during more than 400 different autopsies, he was able to identify salivary gland melanocytes in only one of the evaluated subjects.

In light of information from past case reports, the diagnosis of primary malignant melanoma of the parotid gland is performed according to the criteria listed below:

- (i) The presence of a predominantly intraparotid mass.
- (ii) The absence of any lymph node-originated tissue within the mass.

- (iii) The absence of any other malignant melanoma on the patient's head and neck, including areas such as the nose, mouth, facial skin, esophagus, and pharynx (a thorough examination of the head and neck should be performed).
- (iv) The absence of any previously excised malignant melanoma masses or of any gradually enlarging pigmented skin lesions.

As our case satisfied all of the abovementioned criteria, a pre-diagnosis of primary MM of the parotid gland was considered.

Amelanotik malign melanom is a rare type of MM that is observed in only 2%–8% of cases (9). The amount of literature on primary MM of the parotid gland is very limited, and reports of cases with AMMs primary to the parotid gland are even rarer. To our knowledge, there is only one previous case report of AMM primary to the parotid gland. The patient in question underwent treatment involving total parotidectomy; however, the patient died five months after surgery due to extensive metastases (10).

The patient in our current case had no history of prior melanomas or gradually enlarging pigmented skin lesions. The patient's tumor also demonstrated rapid growth. The presence of primary AMM of the parotid gland was confirmed following the patient's immunohistochemical analysis and pathology report. It is difficult to diagnose AMM because it can mimic other lesions, such as inflammatory processes or benign or malignant tumors. If AMM is suspected after the diagnosis of malignant melanoma, AMMs can be effectively distinguished by immunohistochemically assessing the expression of S100 protein and by HMB45 analysis.

Following the diagnosis of AMMs, the treatment protocol is generally similar to those employed for pigmented melanomas. AMMs generally have poorer prognoses than pigmented melanomas; this is believed to be associated with their often late diagnosis. As our patient refused to undergo surgery for his primary AMM of the parotid gland, he was referred to the oncology department for medical treatment.

Conclusion

To our knowledge, this is the second case report of primary AMM of the parotid gland. Although AMMs are rare, it is important to bear in mind that a rapidly growing tumor within the parotid area can actually be a primary MM or an AMM of the parotid gland itself.

Informed Consent: Informed consent was obtained from patients who participated in this study.

Peer-review: Externally peer-reviewed.

Author Contributions: Concept - E.A.Ö.K., Ç.K.E., Ş.A.; Design - E.A.Ö.K., Ç.K.E., Ş.A.; Supervision E.A.Ö.K., Ç.K.E., Ş.A.; Funding - E.A.Ö.K., Ç.K.E., Ş.A.; Materials - Ş.A.; Data Collection and/or Processing - E.A.Ö.K., Ç.K.E., Ş.A.; Analysis and/or Interpretation - E.A.Ö.K., Ç.K.E., Ş.A.; Literature Review - E.A.Ö.K., Ç.K.E., Ş.A.; Writing - E.A.Ö.K., Ç.K.E., Ş.A.; Critical Review - E.A.Ö.K., Ç.K.E., Ş.A.

Conflict of Interest: No conflict of interest was declared by the authors.

Financial Disclosure: The authors declared that this study has received no financial support.

Hasta Onamı: Hasta onamı bu çalışmaya katılan hastalardan alınmıştır.

Hakem Değerlendirmesi: Dış bağımsız.

Yazar Katkıları: Fikir - E.A.Ö.K., Ç.K.E., Ş.A.; Tasarım - E.A.Ö.K., Ç.K.E., Ş.A.; Denetleme - E.A.Ö.K., Ç.K.E., Ş.A.; Kaynaklar - E.A.Ö.K., Ç.K.E., Ş.A.; Malzemeler - Ş.A.; Veri Toplanması ve/veya İşlemesi - E.A.Ö.K., Ç.K.E., Ş.A.; Analiz ve/veya Yorum - E.A.Ö.K., Ç.K.E., Ş.A.; Literatür Taraması - E.A.Ö.K., Ç.K.E., Ş.A.; Yazıyı Yazan - E.A.Ö.K., Ç.K.E., Ş.A.; Eleştirel İnceleme - E.A.Ö.K., Ç.K.E., Ş.A.

Çıkar Çatışması: Yazarlar çıkar çatışması bildirmemişlerdir.

Finansal Destek: Yazarlar bu çalışma için finansal destek almadığını belirtmiştir.

References

1. Bodenham DC. Malignant melanoma of the head and neck. *Excerpta Medica* 1975; 85-91.
2. Ballantyne AJ. Malignant melanoma of the skin of the head and neck. An analysis of 405 cases. *Am J Surg* 1970; 120: 425-31. [\[CrossRef\]](#)
3. Prayson RA, Sebek BA. Parotid gland malignant melanomas. *Arch Pathol Lab Med* 2000;124: 1780-4.
4. Woodward RT, Shepherd NA, Hensher R. Malignant melanoma of the parotid gland: a case report and literature review. *Br J Oral Maxillofac Surg* 1993; 31: 313-5. [\[CrossRef\]](#)
5. Barbieri M, Gentile R, Cordone MP, Mora R, Mora F. Primitive malignant melanoma of the parotid gland. *ORL J Otorhinolaryngol Relat Spec* 2002; 64: 297-9. [\[CrossRef\]](#)
6. Bussi M, Cardarelli L, Riontino E, Valente G. Primary malignant melanoma arising in the parotid gland: case report and literature review. *Tumori* 1999; 85: 523-5.
7. Takeda Y. Melanocytes in the human parotid gland. *Pathol Int* 1997; 47: 581-3. [\[CrossRef\]](#)
8. Greene GW Jr, Bernier JL. Primary malignant melanomas of the parotid gland. *Oral Surg Oral Med Oral Pathol* 1961; 14: 108-16. [\[CrossRef\]](#)
9. Pizzichetta MA, Talamini R, Stanganelli I, Puddu P, Bono R, Argenziano G, et al. Amelanotic/hypomelanotic melanoma: clinical and dermoscopic features. *Br J Dermatol*. 2004; 150: 1117-24. [\[CrossRef\]](#)
10. Gao N, Li LJ, Li Y, Wang L. Primary amelanotic malignant melanoma of the parotid gland: a case report. *J Int Med Res* 2008; 36: 1435-9. [\[CrossRef\]](#)