

# Aneurysmal Fibrous Histiocytoma in Nasal Vestibule Mucosa

## Nazal Vestibül Mukozasında Anevrizmal Fibröz Histiyoisitoma

Meltem Akpınar<sup>1</sup>, Özgür Yiğit<sup>2</sup>, Yusuf Muhammed Durna<sup>2</sup>, Özgür Şekercan<sup>4</sup>, Semiha Battal Havare<sup>3</sup>

### Abstract / Özet

Aneurysmal fibrous histiocytoma is a different variant of dermatofibroma, characterized by blood-filled spaces within the fibroblastic tumor. In addition to the typical features of a dermatofibroma, it contains large cleft-like or cavernous blood-filled spaces with numerous hemosiderin pigments. This tumor accounts for less than 2% of all fibrous histiocytomas, and it is typically known to occur in the extremities of middle-aged patients. Clinically, they are larger than cutaneous fibrous histiocytomas in size, may be blue, black, or dark red in color, and may have a cystic consistency. They show symptoms of pain and rapid growth. Knowing the characteristics of this rare lesion is important in terms of the differential diagnosis of other malignant mesenchymal neoplasms. In this article, a case of nasal vestibule skin-induced aneurysmal fibrous histiocytoma has been presented in the literature.

**Keywords:** Vestibule, histiocytoma, fibrous

Anevrizmal fibröz histiositoma fibrohistiositik tümör içinde kan dolu boşluklar ile karakterize dermatofibromanın farklı bir varyantıdır. Tipik bir dermatofibroma özelliklerine ek olarak, çok sayıda hemosiderin pigmentler ile büyük yarık benzeri veya kavernöz kan dolu boşluk içerir. Bu tümörler tüm fibroz histiositomaların %2 den daha azını oluşturmakta ve daha çok orta yaşlı kişilerde ekstremitelerde görülmektedir. Klinik olarak kutanöz fibröz histiositomadan daha büyük ve mavi, siyah ya da koyu kırmızı renkte ve kistik bir kıvamda olabilir. Ağrı ve hızlı büyüme semptomları gösterebilirler. Bu nadir lezyonların özelliklerini bilmek, diğer malign mezenkimal neoplazmların ayırıcı tanısı açısından önemlidir. Bu yazıda nazal vestibül cilt kaynaklı anevrizmal fibröz histiositom olgusu literatür eşliğinde sunulmuştur.

**Anahtar Kelimeler:** Vestibül, histiyositoma, fibröz

This study was presented as the 8<sup>th</sup> Turkish Congress of Rhinology, 24-27 May 2014, Antalya, Türkiye.

<sup>1</sup>Clinic of Otorhinolaryngology, Şişli Etfal Training and Research Hospital, İstanbul, Türkiye

<sup>2</sup>Clinic of Otorhinolaryngology, İstanbul Training and Research Hospital, İstanbul, Türkiye

<sup>3</sup>Clinic of Otorhinolaryngology, Suluova State Hospital, Amasya, Türkiye

<sup>4</sup>Clinic of Pathology, İstanbul Training and Research Hospital, İstanbul, Türkiye

### Address for Correspondence

#### Yazışma Adresi:

Yusuf Muhammed Durna, Clinic of Otorhinolaryngology, İstanbul Training and Research Hospital, İstanbul, Türkiye  
Phone: +90 530 977 11 32  
E-mail: yusufmdkbb@gmail.com

Received/Geliş Tarihi:  
18.09.2014

Accepted/Kabul Tarihi:  
07.04.2015

© Copyright 2015 by Available online at  
www.istanbulmedicaljournal.org

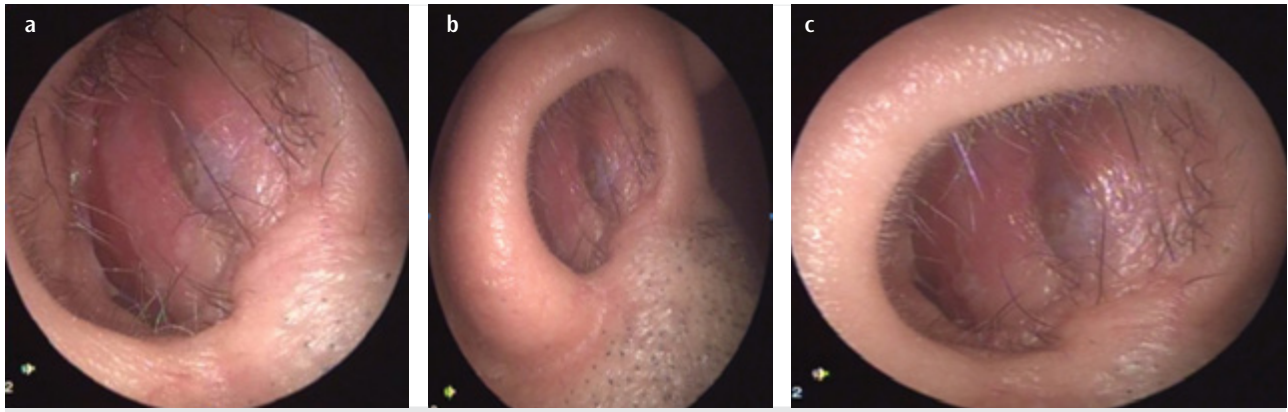
© Telif Hakkı 2015 Makale metnine  
www.istanbultipdergisi.org web sayfasından  
ulaşılabilir.

## Introduction

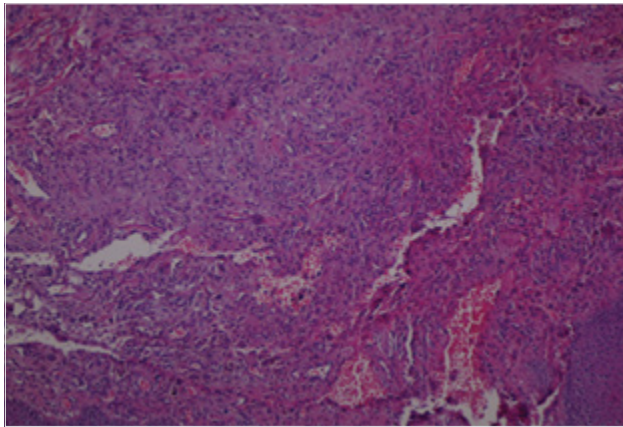
Aneurysmal fibrous histiocytoma is a different variant of dermatofibroma, characterized by blood-filled spaces within the fibroblastic tumor. These tumors constitute less than 2% of all fibrous histiocytomas and are mostly seen in the extremities of middle-aged persons (1, 2). Clinically, they are bigger than cutaneous fibrous histiocytomas, are blue, black, or dark red in color, and may have a cystic consistency. They show symptoms of pain and rapid growth. In 1981, the first case series are reported from Santa Cruz et al. (3) Knowing the rare features of lesions is important for the differential diagnosis of other malignant mesenchymal neoplasms. Aneurysmal fibrous histiocytomas have the potential to get the wrong diagnosis and differential diagnosis; therefore, malignant melanoma, Kaposi's sarcoma, spindle cell hemangioma, angiosarcoma, and angiomatoid fibrous histiocytoma should be considered (4). Clinically, the aneurysmal fibrous histiocytoma has a tendency to local recurrence more than just an ordinary fibrous histiocytoma; specifically, those histiocytomas that have not been completely excised may have the ability to metastasize, as it is reported (5). This article presents a case of aneurysmal fibrous histiocytoma induced by nasal vestibular skin together with literature.

## Case Report

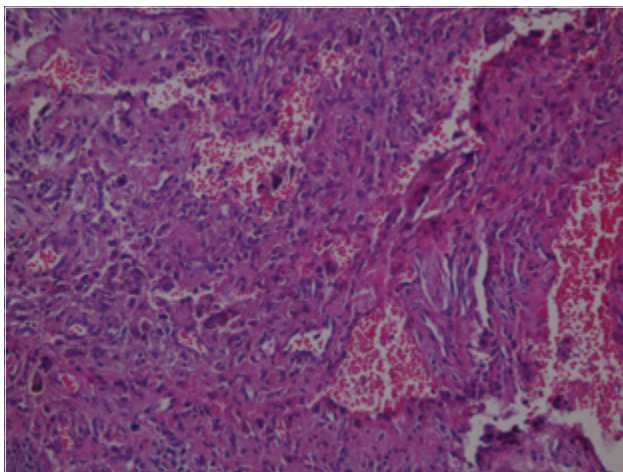
A 67-year-old male patient was admitted to our clinic almost 1 year ago because of the complaints of swelling on the right nasal vestibule. During the anterior rhinoscopy examination of the patient, it was observed that there were approximately 1x1 cm continuous sloping, purple lesions in the right nasal cavity localized to the vestibule (Figures 1a-c). In the patient under general anesthesia, the lesion was excised around a mass of approximately 0.8 mm, and healthy mucosa was left. As a result of the patient's pathology, aneurysmal fibrous histiocytoma was reported. In the microscopic examination of the lesion that was stained with hematoxylin and eosin stain, hemorrhagic, dilated, cavernous vascular channels were observed in the form of slit-like spaces (Figures 2, 3). The patient had no features in postoperative inspections, and we have continued to follow him up. Written informed consent was obtained from the patient who participated in this study.



**Figure 1. a-c.** During the anterior rhinoscopy examination of the patient, there were approximately 1 x 1 cm continuous sloping, purple lesions in the right nasal cavity localized to the vestibule



**Figure 2.** Histopathologic examination under H&E stain revealed hemorrhagic, dilated vascular spaces (H&E stain; original magnification x40)



**Figure 3.** Histopathologic examination under H&E stain revealed hemorrhagic, dilated, cavernous vascular slit-like spaces (H&E stain; original magnification x100)

## Discussion

Dermatofibroma (fibrous histiocytoma) is one of the most common types of cutaneous soft tissue lesions (6). It is more frequent in middle-aged adults and has a slight female predominance. Majority of lesions are present as small, raised, hyperkeratotic, cutaneous nodules with a reddish-brown surface (6, 7). A significant

part of dermatofibroma is associated with previous minor local trauma, particularly insect bites. Eruptive lesions were observed in the context of immunosuppression, HIV infection, highly active antiretroviral therapy (HAART), and pregnancy (8).

Several types of dermatofibroma have been reported in the literature (6, 9). They are essentially distinguished by their histopathological characteristics. However, it is important to note that histological features of several variants can coexist in the same lesion (10). It is important to establish correct diagnosis because some variants also have distinct clinical presentations and different rates of local recurrence. Rare cases of metastasis have also been described (7, 11).

Santa Cruz et al. (3), were the first who defined “aneurysmal fibrous histiocytoma” as a special variant of cutaneous fibrous histiocytoma. This variant usually represents less than 2% of dermatofibromas and is typically known to occur in the limbs of middle-aged persons (7). In our case, the tumor was localized in the nasal vestibule, as distinct from the cases mentioned in the literature. It has slightly higher recurrence rates (20%) compared with those of other fibrous histiocytomas (1, 2). In our case, recurrences were unidentified during inspections made within the postoperative 6 months, and we have continued to follow him up.

Another tumor, which is similarly called, is “angiomatoid” fibrous histiocytoma, and it is usually located in the subcutaneous tissue. These lesions are described to be surrounded by the lymphoid tissue as a characteristic appearance. These tumors are distinguished from the aneurysmal fibrous histiocytoma with those characteristics (12).

Among the differential diagnosis of aneurysmal fibrous histiocytoma, malignant melanoma, Kaposi's sarcoma, spindle cell hemangioma, angiosarcoma, and angiomatoid fibrous histiocytoma should be considered (4). The small number of tumor cells in blood-filled cavities formed by the extravasation of red cells may result in the misleading diagnosis of aneurysmal fibrous histiocytoma (1). Previous publications have revealed that the loss of expressions of factor XIII in stromal cells, which surround blood-filled spaces, causes the formation of cavities by disrupting the stromal instability (13). The enlarged spaces become filled with blood, and with the outgoing pressure, they typically consist of cavernous or angiomatoid areas (14). In the microscopic examination of staining with hematoxylin and eosin in our case, hemorrhagic, dilated, cavernous vascular channels resembling slit-like spaces were identified.

As immunohistochemistry, the aneurysmal fibrous histiocytomas are stained negative with the factor XIIIa, CD34, CD31, CD68, and desmine but strongly positive with vimentin (1).

The aneurysmal fibrous histiocytoma clinically tends to local recurrence and has been reported to be even capable of metastatic spreading. Guillou et al. (15), have reported that the greatest risk factors for metastasis are tumor size, necrosis, repeated local recurrence, high cellularity, aneurysmal changes, and a high mitotic activity. During the past years, a few examples of cellular, aneurysmal, atypical dermatofibromas as well as those occurring on the face and in deep soft tissues which metastasized to lymph nodes and the lungs and even caused death of patients in some instances have been reported (16, 17). Dermatofibroma usually show no chromosomal aberrations, but the vast majority of sarcomas typically display a high level of genomic instability manifested by numerous chromosomal aberrations. It has been shown that cases of so-called malignant fibrous histiocytoma (pleomorphic sarcoma not otherwise specified) show multiple genetic aberrations in most of the cases analyzed (18-20), whereas karyotypic alterations in deep fibrous histiocytoma are sporadic and rare (21).

In aneurysmal cutaneous fibrous histiocytomas, knowing characteristics, such as the presence of hemorrhagic pseudocysts, extravasation of red blood cells, and high vascularity, is important to distinguish these tumors between angiomatoid fibrous histiocytomas and cutaneous malignancies of mesenchymal origin (22).

## Conclusion

As a rare case, aneurysmal fibrous histiocytomas have the potential to interfere with other malignant mesenchymal neoplasms in the stage of diagnosis and are skin lesions with high recurrence rates, which should be kept in mind.

**Informed Consent:** Written informed consent was obtained from patient who participated in this study.

**Peer-review:** Externally peer-reviewed.

**Author Contributions:** Concept - Y.M.D., Ö.Y.; Design - Ö.Y., S.B.H.; Supervision - Ö.Ş., M.D.; Funding - Ö.Y., M.A.; Materials - M.A., S.B.H.; Data Collection and/or Processing - Ö.Ş., Y.M.D.; Analysis and/or Interpretation - Ö.Y., M.A.; Literature Review - Y.M.D., S.B.H.; Writer - Y.M.D., Ö.Ş.; Critical Review - Ö.Y., S.B.H., M.A.; Other - M.A., Ö.Y.

**Conflict of Interest:** No conflict of interest was declared by the authors.

**Financial Disclosure:** The authors declared that this study has received no financial support.

**Hasta Onamı:** Yazılı hasta onamı bu çalışmaya katılan hastadan alınmıştır.

**Hakem değerlendirmesi:** Dış bağımsız.

**Yazar Katkıları:** Fikir - Y.M.D., Ö.Y.; Tasarım - Ö.Y., S.B.H.; Denetleme - Ö.Ş., M.D.; Kaynaklar - Ö.Y., M.A.; Malzemeler - M.A., S.B.H.; Veri toplanması ve/veya işlemesi - Ö.Ş., Y.M.D.; Analiz ve/veya yorum - Ö.Y., M.A.; Literatür taraması - Y.M.D., S.B.H.; Yazıyı yazan - Y.M.D., Ö.Ş.; Eleştirel inceleme - Ö.Y., S.B.H., M.A.; Diğer - M.A., Ö.Y.

**Çıkar Çatışması:** Yazarlar çıkar çatışması bildirmemişlerdir.

**Finansal Destek:** Yazarlar bu çalışma için finansal destek almadıklarını beyan etmişlerdir.

## References

- Calonje E, Fletcher CD. Aneurysmal benign fibrous histiocytoma: clinico-pathological analysis of 40 cases of a tumour frequently misdiagnosed as a vascular neoplasm. *Histopathology* 1995; 26: 323-31. [\[CrossRef\]](#)
- Sheehan KM, Leader MB, Sexton S, Cunningham F, Leen E. Recurrent aneurysmal fibrous histiocytoma. *J Clin Pathol* 2004; 57: 312-3. [\[CrossRef\]](#)
- Santa-Cruz DJ, Kyriakos M. Aneurysmal ('angiomatoid') fibrous histiocytoma of the skin. *Cancer* 1981; 47: 2053-61. [\[CrossRef\]](#)
- Sood U, Mehregan AH. Aneurysmal (angiomatoid) fibrous histiocytoma. *J Cutan Pathol* 1985; 12: 157-62. [\[CrossRef\]](#)
- Guillou L, Gebhard S, Salmeron M, Coindre JM. Metastasizing fibrous histiocytoma of the skin: a clinicopathologic and immunohistochemical analysis of three cases. *Mod Pathol* 2000; 13: 654-60. [\[CrossRef\]](#)
- Han TY, Chang HS, Lee JH, Lee WM, Son SJ. A clinical and histopathological study of 122 cases of dermatofibroma (benign fibrous histiocytoma). *Ann Dermatol* 2011; 23: 185-92. [\[CrossRef\]](#)
- Luzar B, Calonje E. Cutaneous fibrohistiocytic tumours - an update. *Histopathology* 2010; 56: 148-65. [\[CrossRef\]](#)
- Zaccaria E, Rebora A, Rongioletti F. Multiple eruptive dermatofibromas and immunosuppression: report of two cases and review of the literature. *Int J Dermatol* 2008; 47: 723-7. [\[CrossRef\]](#)
- Weedon D. Dermatofibroma (Fibrous histiocytoma). In: Weedon D. *Skin pathology*. 2nd ed. London: Churchill Livingstone; 2002. p. 930-3.
- Zelger BG, Sidoroff A, Zelger B. Combined dermatofibroma: co-existence of two or more variant patterns in a single lesion. *Histopathology* 2000; 36: 529-39. [\[CrossRef\]](#)
- Calonje E, Brenn T, Lazar A, McKee P. McKee's pathology of the skin with clinical correlations. 4th ed. Edinburgh: Elsevier Saunders; 2012. p. 1643-62.
- Botrus G, Sciot R, Debiec-Rychter M. Cutaneous aneurysmal fibrous histiocytoma with at (12;19) p12;q13 as the sole cytogenetic anomaly. *Cancer Genet Cytogenet* 2006; 164: 155-8. [\[CrossRef\]](#)
- Inui S, Itami S, Yoshikawa K. Aneurysmal fibrous histiocytoma showing transition from factor XIIIa-positive to negative. *J Dermatol* 2002; 29: 744-7. [\[CrossRef\]](#)
- Niemi KM. The benign fibrohistiocytic tumours of the skin. *Acta Derm Venereol Suppl (Stockh)* 1970; 50:Suppl 63: 61-6.
- Guillou L, Gebhard S, Salmeron M, Coindre JM. Metastasizing fibrous histiocytoma of the skin: a clinicopathologic and immunohistochemical analysis of three cases. *Mod Pathol* 2000; 13: 654-60. [\[CrossRef\]](#)
- De Hertogh G, Bergmans G, Molderez C, Sciot R. Cutaneous cellular fibrous histiocytoma metastasizing to the lungs. *Histopathology* 2002; 41: 85-6. [\[CrossRef\]](#)
- Osborn M, Mandys V, Beddow E, Ladas G, Florio R, Sheppard MN, et al. Cystic fibrohistiocytic tumours presenting in the lungs: primary or metastatic disease. *Histopathology* 2003; 43: 556-62. [\[CrossRef\]](#)
- Larramendy ML, Tarkkanen M, Blomqvist C, Virolainen M, Wiklund T, Asko-Seljavaara S, et al. Comparative genomic hybridization of malignant histiocytoma reveals a novel prognostic marker. *Am J Pathol* 1997; 151: 1153-61.
- Chibon F, Mariani O, Mairal A, Derre J, Coindre JM, Terrier P, et al. The use of clustering software for the classification of comparative genomic hybridization data. An analysis of 109 malignant fibrous histiocytomas. *Cancer Genet Cytogenet* 2003; 141: 75-8. [\[CrossRef\]](#)
- Weng WH, Wejde J, Ahlen J, Pang ST, Lui WO, Larsson C. Characterization of large chromosome markers in a malignant fibrous histiocytoma by spectral karyotyping, comparative genomic hybridization (CGH9, and array CGH. *Cancer Genet Cytogenet* 2004; 150: 27-32. [\[CrossRef\]](#)
- Frau DV, Erdas E, Caria P, Ambu R, Dettori T, Faa G, et al. Deep fibrous histiocytoma with a clonal karyotypic alteration: molecular cytogenetic characterization of a t(16;17)(p13.3;q21.3). *Cancer Genet Cytogenet* 2010; 202: 17-21. [\[CrossRef\]](#)
- Yang P, Hirose T, Hasegawa T, Seki K, Hizawa K. Aneurysmal fibrous histiocytoma of the skin. A histological, immunohistochemical, and ultrastructural study. *Am J Dermatopathol* 1995; 17: 179-84. [\[CrossRef\]](#)