



Abstract

# Relapsing Polychondritis that Recovers Rapidly with a Single Dose of Steroid

Abdurrahman Bozkurtan, Süheyl Haytoğlu, Soner Kadıköylü, Umut Aslan, Osman Kürşat Arıkan

Relapsing polychondritis is a rare, autoimmune, multisystemic disease that presents with episodic inflammatory process of the cartilages. We report a case of a 48-year-old woman who presented to our otolaryngology clinic with complaints of pain, eritema, edema on both auricles, itching, and desquamation on hairy skin. She had a history of multiple episodes of these complaints for 2 years. Biopsy was performed in both the auricles. The pathological examination revealed that the perichondrial area was infiltrated by inflammatory cells and fibrosis was composed. On the basis of the pathological examination and clinic correlation, relapsing polychondritis was diagnosed. Low-dose corticotherapy was administered and in the first 8 h, significant healing was observed. This case indicated that clinicians consider relapsing polychondritis and the demonstrative therapy by low doses of corticosteroids for differential diagnosis and therapy of relevant cases.

**Keywords:** Relapsing polychondritis, psoriasis, steroid

## Introduction

Relapsing polychondritis is a rare, autoimmune disease that affects multiple systems and presents with episodic inflammatory attacks in articular and non-articular cartilage tissues. Antibodies that develop against type II collagen play a role in its pathogenesis. Immunoglobulin G (IgG) antibodies against type II collagen have been found in the serum of 50% of patients with this condition. In relapsing polychondritis, inflammation can be observed in regions rich in proteoglycans, such as the heart, blood vessels, and inner ear. In addition, vasculitis that involves the skin and internal organs can develop (1-3). In more than 30% of patients, other autoimmune diseases, including leukocytoclastic vasculitis, rheumatoid arthritis, systemic lupus erythematosus, hemolytic anemia, Hashimoto's thyroiditis, thymoma, vitiligo, and psoriasis, may also coexist (4).

The mean annual incidence of this disease is 3.5 per million. It can be seen in all age groups, but it has been mostly reported between the ages of 40 and 50 years, with a female:male ratio of 3:1 (1-3, 5). Its diagnosis is generally established clinically, pathologically, and radiologically because it is not associated with a specific laboratory finding (6).

In this case, a patient who had suffered long-term symptoms and healing with palliative therapies or without any therapy was clinically and histopathologically diagnosed with relapsing polychondritis and treated with short-term low-dose corticotherapy. We present this case to bring attention to this rarely seen disease.

## Case Report

A female patient (age, 48 years; weight, 88 kg) was admitted to our outpatient clinic with a complaint of itching in both ears that began 5 years ago and recurred almost every month; she also had complaints of edema, erythema, and pain when touched on both auricles that had lasted for the past 2 years. These complaints were particularly more apparent in the auricle of the right ear. She was administered various drugs (for example, topical steroids and oral antibiotics) at different health centers where she was previously admitted.

The patient stated that she had serious itching and desquamation on hairy skin for 5 years; she also sometimes had red round spots on different regions of the body and skin findings that spread to other regions on itching and that could heal by themselves. She specified that she had been diagnosed with psoriasis by the department of dermatology at our hospital 2 months ago. The patient was asked about other systemic findings in detail. She complained of pain in her joints for approximately 10 years, but it was not severe and/or continuous. She had tearing, itching, and redness in her eyes for the last 3 years, which spontaneously resolved without using any medica-

Clinic of Otorhinolaryngology, Adana Numune Training and Research Hospital, Adana, Türkiye

As poster presentation, the 35<sup>th</sup> Turkish National Otolaryngology-head and Neck Surgery Congress, 2-6 November 2013, Antalya, Türkiye.

### Address for Correspondence:

Abdurrahman Bozkurtan, Adana Numune Eğitim ve Araştırma Hastanesi, Kulak Burun Boğaz Kliniği, Adana Türkiye  
Phone: +90 506 781 42 44  
E-mail: abozkurtan@gmail.com

Received:  
18.08.2014

Accepted:  
02.11.2014

© Copyright 2015 by Available online at  
www.istanbulmedicaljournal.org

tions over 1–2 weeks. She did not define any other complaints, except those described above. She had a history of previous surgeries because of gynecological diseases 18 years ago, and her family history revealed that her mother and sister had eczema.

Her ear, nose, and throat examination revealed diffuse erythema and edema in both auricles and in the external auditory canal, but the results of the oropharyngeal and laryngeal examinations were normal (Figure 1). In her comprehensive audiological examination, her hearing was within normal limits, and there was no evidence of inner ear involvement. Her dermatological evaluation revealed plaques with squam on hairy skin, and crusts on erythematous bases were observed on both knees. Anisometropic amblyopia was detected in the left eye, and her biomicroscopy was normal. On her gynecological examination, we determined that her previous operation was a right ovariectomy (probably associated with an ovarian cyst). The results of the other systemic examinations were normal.

The patient's hemogram, sedimentation, routine biochemistry values, thyroid function tests, and routine urine analysis were within normal limits. Her C-reactive protein (CRP) level (0.6 mg/dL) was slightly higher than normal. The rheumatoid factor (RF) and anti-streptolysin O (ASO) levels were negative. Her IgA level (84.14 mg/dL) was slightly lower than normal, and her IgG and IgM levels were normal. The C3 level (77 mg/dL) was lower than the normal value, and the C4 level was normal. The perinuclear neutrophil antibody/antineutrophil cytoplasmic antibody (pANCA/cANCA) profile titer was <1:10, which was within normal limits.

The patient also underwent a detailed radiologically evaluation. On a dynamic expiratory thoracic tomography, emphysema and mild interstitial icy glass appearance in both lower zones were detected. The patient was referred to the Department of Chest Diseases at our hospital. Follow-up was then recommended for this patient because her examination and respiratory functioning tests were normal, and she did not have any further complaints at this time. Her renal Doppler ultrasonography results were reported as normal. Her echocardiograph examination revealed calcification in the aorta and mitral valves and left ventricular diastolic dysfunction (Stage 1). These results were evaluated by the Department of Cardiology, and no treatment was required.

The histopathological examination of her biopsy specimen taken from the auricle by covering the cartilage tissue indicated degeneration in the collagen in the dermis under the acanthotic and hyperplastic stratified squamous epithelium, severe active chronic inflammatory cell infiltration that also infiltrated fat tissue, and capillary vein proliferation with neutrophils, fibrosis, and lymphocytes in the perichondrial region.

The patient was started on intravenous corticotherapy. The treatment began with 40 mg of intravenous methylprednisolone. Because a considerable improvement was observed at the end of the 8<sup>th</sup> hour of the treatment (Figure 2), the drug was decreased by 10 mg each day; the treatment was discontinued on the 5<sup>th</sup> day (Figure 4, 5). The patient was followed up without treatment (Figure 6).

## Discussion

Relapsing polychondritis should be an early consideration in bilateral recurrent auricular inflammation. This finding is seen in 85%

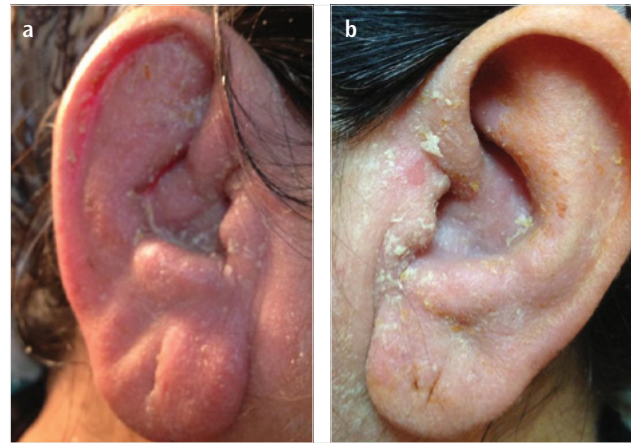


Figure 1. a, b. Right (a) and left (b) auricles before treatment

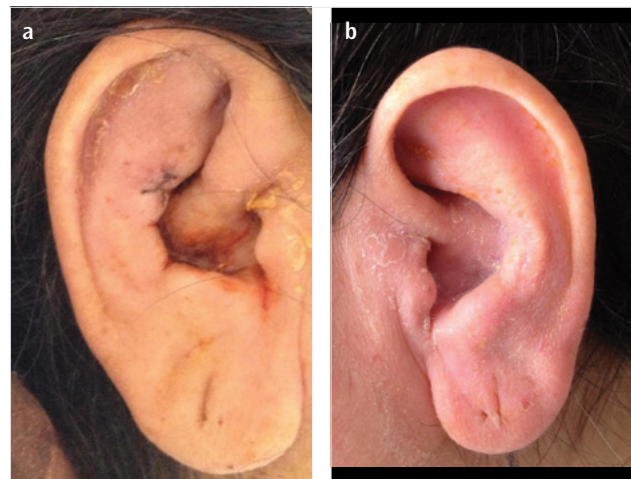

Figure 2. a, b. Right (a) and left (b) auricles at 8 h post treatment

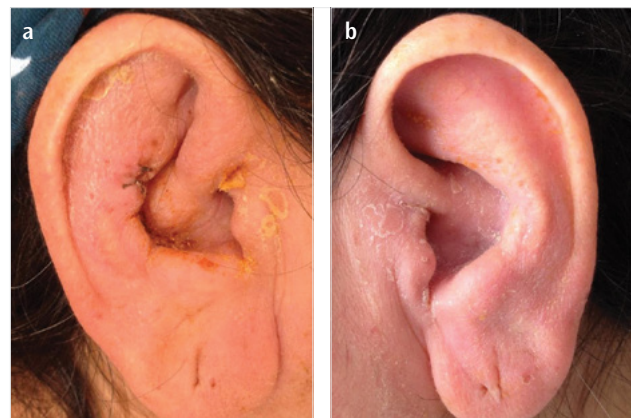


Figure 3. a, b. Right (a) and left (b) auricles at 24 h post treatment

of patients who are diagnosed with this condition. Inner ear involvement has also been rarely reported (7). Erythema, tenderness, and edema, which suddenly develop unilaterally or bilaterally in the cartilage of the external ear in the auricular chondrite, have also been observed in this disease. The acute inflammation often regresses spontaneously in 1–2 weeks, but it can recur after weeks or months. Long-term and recurrent inflammatory episodes lead to fibrosis and deconstruction of the cartilage tissue and can cause a deformity in the auricle. Nausea, vomiting, tinnitus, ataxia, and



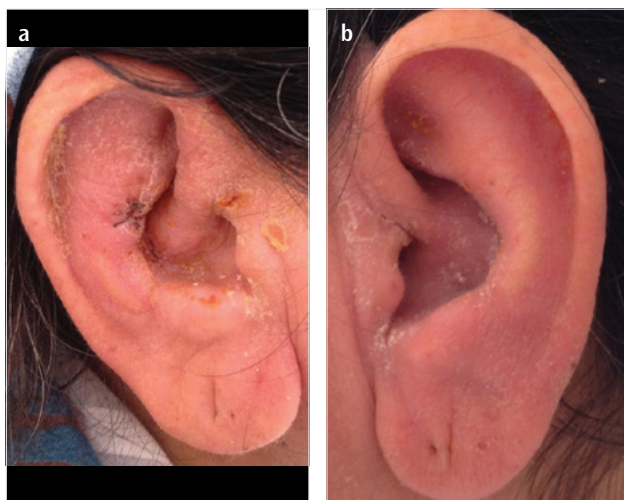


Figure 4. a, b. Right (a) and left (b) auricles at 48 h post treatment

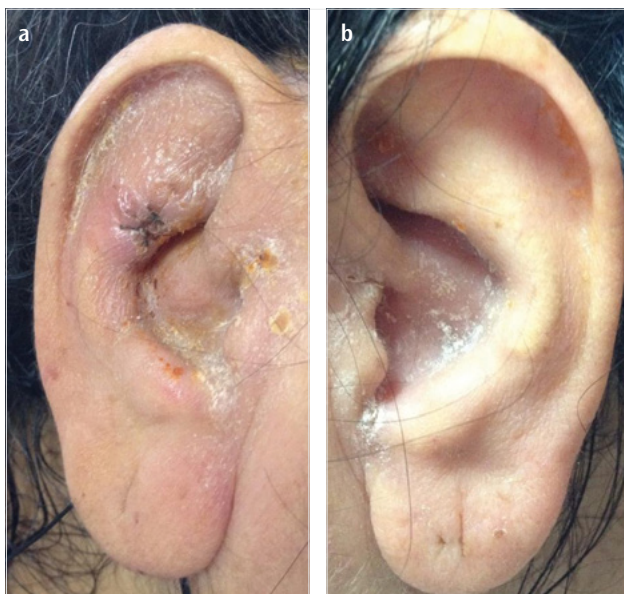

Figure 5. a, b. Right (a) and left (b) auricles at 72 h post treatment

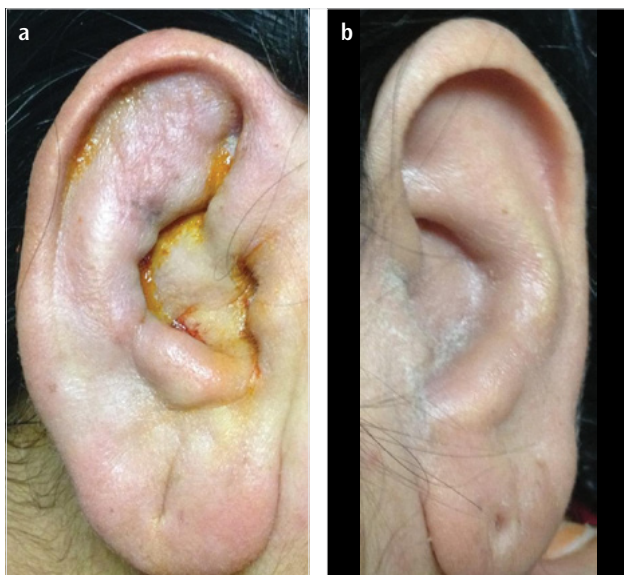


Figure 6. a, b. Right (a) and left (b) auricles at the 24<sup>th</sup> day control

hearing loss associated with inner ear damage may also be present. In our patient, no inner ear involvement was identified, and her hearing test results were normal.

Nasal chondritis is seen in 54%–70% of these patients. This condition is characterized by sudden inflammation that regresses spontaneously after a few days. If the attacks recur, a cartilage collapse occurs, causing a saddle nose deformity. It can present with nasal pain, erythema, sweating, rhinorrhea, and sometimes epistaxis (5). In our case, nasal symptoms were not observed.

Arthropathy is the second most common clinical finding in relapsing polychondritis (50%–80%). The arthritis is generally asymmetrical, migratory, seronegative, and non-destructive. It clinically varies from temporary arthralgia to mono, pauci, or polyarticular disease, with symmetrical or asymmetrical synovitis; the arthritis involves either large joints or peripheral and parasternal joints (such as costochondral, manubriosternal, sternoclavicular). The presence of peripheral arthritis is associated with diffuse disease and poor prognosis (8). In our case, mild and rarely seen symptoms related to arthritis or arthralgia were seen.

Respiratory system symptoms are also common and are the most important cause of mortality. They are observed at the beginning of the disease in 25%–50% of patients. The most affected regions are the larynx, trachea, and bronchi. Cartilage involvement presents with dysphonia, aphonia, non-productive cough, dyspnea, and wheezing, and it can often be confused with asthma (9).

Ocular involvement is also another main finding. Scleritis, episcleritis, and conjunctivitis are more frequently observed (10). These findings can mildly or apparently decrease vision.

Cutaneous findings are observed in 50% of these patients. The most frequently seen findings are vasculitis and erythema nodosum-like lesions. Other skin signs include oral aphthae, angioedema, urticaria, livedo reticularis, lichen planus, vitiligo, and psoriasis (2, 11, 12). Our patient was diagnosed with psoriasis.

Renal involvement is very rare (10%), and its existence indicates poor prognosis. Pauci-immune crescentic glomerulonephritis, segmental necrotic glomerulonephritis, glomerulosclerosis, and IgA nephropathy, which can generally be revealed with biopsy and continue with hematuria, proteinuria, and sometimes severe renal dysfunction, may be present (13). Aortic insufficiency or aortic aneurysm in association with sudden dilatation in the ascending aorta or aortic valve and renal complications due to renal artery involvement can develop. Renal artery involvement is an indicator of poor prognosis (14).

Furthermore, laboratory findings are important for the diagnosis of relapsing polychondritis. Although there is no specific panel of tests, anemia, leukocytosis, and thrombocytosis can be observed during the active period. The erythrocyte sedimentation rate and CRP levels may also be increased. In some cases, anti-collagen antibodies may be positive in proportion to the severity of the disease (15). The results of all laboratory tests were normal in our case.

In her histopathological examination, disappearance and paling of cells were seen in the normal basophilia of the cartilage, in association with the perichondrial lymphocyte and neutrophil

infiltration. After frequent inflammatory recurrences, the fibrotic tissue replaces the cartilage tissue. In half of the patients, immunoglobulin or complement accumulation can be found on an immunofluorescent examination.

A diagnostic algorithm was defined by McAdam et al. (10) in 1976. The criteria requested for diagnosis are as follows: (a) positivity of at least three criteria, (b) histopathological diagnosis and positivity of at least one criterion, or (c) presence of chondritis in two or more anatomical regions with response to steroids and/or dapsone. Bilateral auricular chondritis was observed in our patient. In addition to the histopathological diagnosis, a rapid response to corticotherapy helped establish the diagnosis of relapsing polychondritis.

The prognosis of the disease is variable, and mortality has been reported at a rate of 30%. Prognosis is poor in patients with laryngotracheal–bronchial involvement. Hoarseness and tenderness of the thyroid cartilage and anterior trachea are symptoms indicating the involvement of this region. Clinically, cough, dyspnea, inspiratory stridor, or rarely hemoptysis is also seen. In serious cases, glottic, subglottic, or laryngeal inflammation developing with edema may require tracheostomy. Recurring attacks can cause a permanent structural defect in the airway, and death due to asphyxia can occur. Upper and lower respiratory tract infections are also frequently encountered. The most common causes of death are airway collapse and lower respiratory tract infections. Cardiovascular complications and infections secondary to steroid therapy are the next most common causes (16).

The determination of respiratory system involvement in early stage reduces the rate of mortality to a great extent. In cases with suspected respiratory system involvement, it is necessary to use dynamic expiratory tomography as a routine imaging technique because it can determine pulmonary pathology at a higher rate (17). A standard protocol has not been recommended for the treatment of relapsing polychondritis. In the presence of mild inflammation in the joints, nose, and ears, non-steroidal anti-inflammatory drugs, dapsone, and colchicine generally provide good results. Systemic steroids are used for acute exacerbations. Glomerulonephritis or laryngotracheal interactions can occur in recurrent cases. Immune suppression can be achieved with systemic steroids, cyclophosphamide, or cytotoxic drugs. Moreover, cyclosporine A has also been utilized in some patients resistant to steroids (18).

## Conclusion

Relapsing polychondritis is a rare, multisystem, inflammatory disease. It is important to know the features of this disease and to initiate appropriate treatment after an early diagnosis.

**Informed Consent:** Written informed consent was obtained from patient who participated in this study.

**Peer-review:** Externally peer-reviewed.

**Author Contributions:** Concept - A.B., S.H., S.K., U.A., O.K.A.; Design - A.B., S.H., S.K., U.A., O.K.A.; Supervision - A.B., S.H., S.K., U.A., O.K.A.; Funding - A.B., S.H.; Materials - A.B., S.H.; Data Collection and/or Processing - A.B., S.H., S.K., U.A.; Analysis and/or Interpretation - A.B., S.H., S.K.; Literature Review - A.B., S.H.; Writer - A.B., S.H.; Critical Review - A.B., S.H.

**Conflict of Interest:** No conflict of interest was declared by the authors.

**Financial Disclosure:** The authors declared that this study has received no financial support.

## References

- Letko, E, Zafirakis P, Baltatzis S, Voudouri A. Relapsing polychondritis: A clinical review. *Semin Arthritis Rheum* 2002; 31: 384-95. [\[CrossRef\]](#)
- Trentham DE, Le CH. Relapsing polychondritis. *Ann Intern Med* 1998; 129: 114-22. [\[CrossRef\]](#)
- Meza J, Remes J, Monta-o A. Policondritis recidivante: presentación de 5 casos y revisión de la literatura. *Rev Mex Reumatol* 2001; 16: 309-14.
- Asadi AK. Relapsing polychondritis. *Dermatol Online J* 2003; 9: 3.
- Kent PD, Michet CJ, Luthra HS. Relapsing polychondritis. *Curr Opin Rheumatol* 2003; 16: 56-61. [\[CrossRef\]](#)
- Harris ED, Budd RC, Genovese MC et al. Relapsing Polychondritis. *Kelley's Textbook Of Rheumatology* 2006; 94: 1541-6.
- Kumakiri K, Sakamoto T, Karahashi T, Mineta H, Takebayashi S. A case of relapsing polychondritis preceded by inner ear involvement. *Auris Nasus Larynx* 2005; 32: 71-6. [\[CrossRef\]](#)
- Balsa A, Expinosa A, Cuesta M, et al. Joint symptoms in relapsing polychondritis. *Clinical and Experimental Rheumatology* 1995; 13: 425-30.
- Segel MS, Godfrey S, Berkman N. Relapsing Polychondritis: reversible airway obstruction is not always asthma. *Mayo Clin Proc* 2004; 79: 407-9. [\[CrossRef\]](#)
- McAdam LP, O'Hanlan MA, Bluestone R, Pearson C. Relapsing polychondritis: Prospective study of 23 patients and a review of the new literature. *Medicine* 1976; 55: 193-215. [\[CrossRef\]](#)
- Ananthakrishna R, Goel R, Padhan P, Mathew J, Danda D. Relapsing polychondritis-case series from South India. *Clin Rheumatol* 2009; 28 Suppl 1: S7-10. [\[CrossRef\]](#)
- Bhattacharjee A, Chakraborty A, Purkaystha P. Prevalence of head and neck cancers in the north east-an institutional study. *Indian J Otolaryngol Head Neck Surg* 2006; 58: 15-9.
- Barzegar C, Vrtovnik F, Devars JF, Mignon F, Pradalier A. Vasculitis with mesangial IgA deposits complicating relapsing polychondritis. *Clin Exp Rheumatol*. 2002; 20: 89-91.
- Chang-Miller A, Okamura M, Torres VE, Michet CJ, Wagoner RD, James VJR. Renal involvement in relapsing polychondritis. *Medicine Baltimore* 1987; 66: 202-17. [\[CrossRef\]](#)
- Ebringer R, Rook G, Swana GT, Bottazzo GF, Doniach D. Autoantibodies to cartilage and type II collagen in relapsing polychondritis and other rheumatologic diseases. *Ann Rheum Dis* 1981; 40: 473-9. [\[CrossRef\]](#)
- Güler M. Relapsing polychondritis (tekrarlayan polikondrit). *Türkiye Klinikleri J Med Sci* 1987; 7: 327-33.
- Lee KS, Ernst A, Trentham DE, Lunn W, Feller-Kopman DJ, Boisselle PM. Relapsing polychondritis: Prevalence of expiratory CT airway abnormalities. *Radiology* 2006; 240: 565-73. [\[CrossRef\]](#)
- Richez C, Dumoulin C, Coutouly X, Schaefferbeke T. Successful treatment of relapsing polychondritis with infliximab. *Clin Exp Rheumatol* 2004; 22: 629-31.