

Unilateral Sudden Sensorineural Hearing Loss after Combined Nasal and Breast Surgery: Case Report

Eş Seanslı Burun ve Meme Cerrahisi Sonrası Tek Taraflı Ani Sensörinöral İşitme Kaybı: Olgu Sunumu

Meltem Esen AKPINAR,¹ Nilgün SÜRMEN ÖNDER,¹ Mazhar ÇELİKOYAR,² Özgür YİĞİT,¹ Elad AZİZLİ¹

SUMMARY

Sudden sensorineural hearing loss (SSHL) is defined as 30 dB or more SHL over at least three consequent audiometric frequencies occurring within three days or less. Excessive upper airway pressure during the induction phase of general anesthesia, Valsalva maneuvers, nitrous oxide administration, microemboli, and variations in cerebrospinal fluid (CSF) pressure are the suggested underlying mechanisms of postoperative SSHL. We report a case of unilateral SSHL after nasal surgery combined with reduction mammoplasty, with a history of a single dose of intravenous gentamicin administration intraoperatively. Despite the early detection, intense follow-up and treatment regimens, satisfactory improvement could not be achieved in the patient's hearing level. SSHL is a possible complication after otologic and cardiac surgeries. SSHL after non-otologic non-cardiac surgery is uncommon. There is no previous SSHL report in the literature associated with combined nasal and breast surgery.

Key words: Sudden hearing loss.

ÖZET

Ani sensörinöral işitme kaybı üç günden kısa sürede birbirini takip eden 3 frekansta 30 dB ya da daha fazla sensörinöral işitme kaybı olarak tanımlanır. Postoperatif ani sensörinöral işitme kaybında altta yatan mekanizmalar; genel anestezinin indüksiyon fazında üst havayolundaki aşırı basınç, valsalva manevrası, nitroz oksit uygulaması, mikroemboli ve beyin omurilik sıvısında basınç değişimi olarak ileri sürülmüştür. Bu yazıda, eş seanslı burun ve meme küçültme cerrahisi sırasında tek doz intravenöz gentamisin uygulanma hikayesi sonrası gelişen tek taraflı ani sensörinöral işitme kaybı olgusu sunuldu. Erken tanı, yakın takip ve tedavi rejimlerine rağmen işitme seviyesinde tatmin edici gelişme kaydedilemedi. Ani sensörinöral işitme kaybı otolojik ve kaydıyak cerrahilerden sonra görülebilen bir komplikasyondur. Kardiyak ve otolojik olmayan cerrahiden sonra görülmesi ise alışılmadık bir durumdur. Eş seanslı nazal ve meme cerrahisi ile bağlantılı literatüre daha önce sunulmuş olgu bulunmamaktadır.

Anahtar sözcükler: Ani işitme kaybı.

INTRODUCTION

Sudden sensorineural hearing loss (SSHL) is defined as 30 dB or more SHL over at least three consequent audiometric frequencies occurring within three days or less.^[1] SSHL after non-otologic surgery although rare has been reported previously in the literature especially after the cardiac and spinal surgery.^[2]

Excessive upper airway pressure during the induction phase of general anesthesia, valsalva maneuvers, nitrous oxide administration, microemboli and variations in cerebrospinal fluid (CSF) pressure are the suggested underlying mechanisms of postoperative SSHL.^[3]

We report a case of unilateral SSHL after nasal

Submitted (Geliş tarihi): 27.02.2011 Accepted (Kabul tarihi): 17.05.2011

¹Istanbul Training and Research Hospital, 2nd Department of Otorhinolaryngology, Istanbul

²Istanbul Surgery Hospital, Istanbul

Correspondence (İletişim): Meltem Esen Akpınar, M.D. e-mail (e-posta): meltemakpinar@hotmail.com

surgery combined with reduction mammoplasty and in this case a single dose of gentamicin IV was administered intraoperatively with the order of plastic surgeon. Institutional review board was taken and informed consent was received from the patient. There is no previous SSHL report in the literature associated with combined nasal and breast surgery

CASE REPORT

A 36-year-old female patient had septorhinoplasty and reduction mammoplasty (breast reduction surgery) with the diagnosis of septal deviation, nasal and breast deformity. Medical history revealed general anesthesia for lipoma excision from shoulder one year ago and no systemic and allergic disease. She was not using regular medication for any purpose and smoking 1.5 pack/day. She was 1.64 m in height and 56 kg in weight. In routine preoperative evaluation the systemic examination findings, ECG, Chest X-ray and blood tests were in normal limits. Midazolam (2 mg iv) was administered as premedication. Total operative time for two surgeries was five hours. Nasal surgery was performed by the otolaryngologists and the breast reduction by plastic surgeons.

For the induction, thiopental sodium (5 mg/kg) and remifentanyl (1 mg/kg) administration was followed by vecuronium bromide (0.1 mg/kg) to facilitate the tracheal intubation and muscle relaxation.

After the induction with 50% NO, 50% O₂ and 1-3% sevoflurane, the maintenance with remifentanyl (0.125-0.250 mg/kg/min) as to the depth of anesthesia. Her intraoperative diastolic and systolic blood pressure was monitored between 60-80 mmHg and 90-120 mmHg respectively. Intraoperative pulse history revealed the range of 80-95 pulse/min. Dexamethasone (4 mg), metoclopramide HCL (10 mg), cefazolin sodium (1 gr) were the additional medications administered intraoperatively. Gentamicin 100 mg was administered intravenously with the order of plastic surgeon in the 3rd hour of the operation. Postoperative medications in her order were cefazolin sodium (2 gr bid, iv), paracetamol (1.5 gr tid, po), pantoprazole HCL (80mg bid, iv), pethidine HCL (100 mg, im) and xylometazoline spray (2 puffs bid, nasally).

On the postoperative 1st day she complained about tinnitus and hearing difficulty in her right ear. Weber test lateralized to right side, tympanic membranes were intact with no apparent pathology in the external ear canal. Audiologic tests revealed profound SNHL in right ear in lower frequencies particularly with absent acoustic reflex. In audiogram pure tone average was 101 dB on right ear with a significant loss in lower frequencies including 1000 Hz (Figure 1). Diagnostic work-up enclosing neurology consultation, laboratory tests (CBC, creatinine,

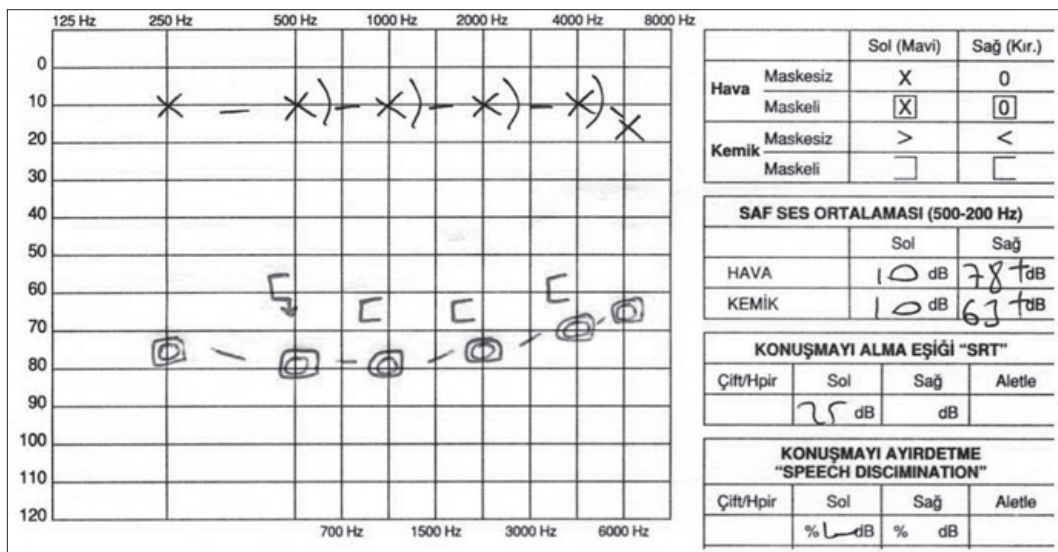


Figure 1. Postoperative 1st day audiogram.

BUN, CRP, B12, folic acid) and cranial magnetic resonance imaging were in normal limits. Trental CR (1.2 gr, bid), trental (100mg, 1.6 mg/min iv), dextran in isotonic NaCl solution (500 ml, 1.5 ml/min iv), methylprednisolone sodium succinate (80 mg iv), acetylsalicylic acid (100 mg), acyclovir (1 gr qid, iv), vitamin E 200 IU, vitamin B1, B6, B12 complex (500 mg, bid) were added her postoperative 1st day order. Hyperbaric O₂ treatment was started on postoperative 2nd day and continued for 20 sessions. She was discharged on postoperative 6th day. Hearing level was followed with serial audiograms on postoperative 3rd, 6th, 8th, 13th and 24th days. On postoperative 3rd day pure tone air and bone conduction average in right ear was 78 dB and 63 dB respectively (Figure 1). At 6 month follow-up her air and bone conduction averages recovered to 58 dB and 50 dB in lower frequencies (Figure 2).

DISCUSSION

Overall incidence of SHL is reported to be between 5 to 20 per 100,000 cases per year.^[3] SSHL after non-otologic surgery is a rare entity mostly reported in association with cardiac bypass surgery. Microemboli occluding internal auditory artery is proposed underlying mechanism of SSHL associated with cardiac surgery. In a 7000 patient series incidence of postoperative SSHL was reported 1 in 1000

cases by Plasse et al.^[4] Spinal surgery is most commonly reported non-otologic non-cardiac surgery associated with SSHL. Although in spinal surgery source of emboli is not clear increased platelet count and adhesiveness could be triggering mechanism in formation of emboli.^[5]

There are multiple mechanisms proposed in progression of postoperative SSHL. Another etiologic factor reported in literature is nitrous oxide usage during general anesthesia. Nitrous oxide administration during general anesthesia cause rapid increase (up to 450 mmHg) in middle ear pressure. This relatively high middle ear pressure compared to inner ear may cause cochlear membrane breaks and perilymph fistula.^[6]

CSF pressure surges, valsalva maneuver, straining are other suggested mechanisms. CSF pressure fluctuations transmitted via cochlear aquaduct to inner ear are thought to elicit membrane rupture.^[7]

In this case intraoperative administration of single dose gentamicin reminded us the ototoxicity. But significant hearing loss in lower frequencies rather than higher frequencies, unilateral hearing loss and absence of vertigo were not consistent with the features of SHL due to ototoxicity.^[8] The major aminoglycoside ototoxicity is irreversible and occurs as the result of the accumulation of aminoglycosides in the

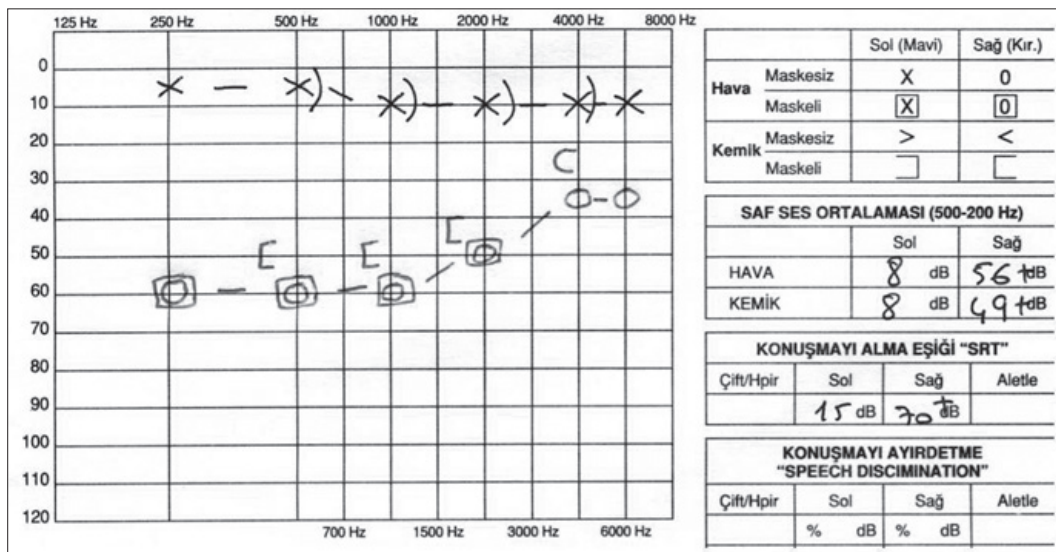


Figure 2. Postoperative follow-up audiogram on 6th month.

perilymph of the inner ear with subsequent damage of the sensory cells of the organ of Corti. Although the mechanism is not known exactly, cochlear damage is usually permanent since cochlear hair cells do not regenerate.^[9] This impairment ends up with permanent hearing loss.^[10] Aminoglycoside induced ototoxicity is reported in individuals with mitochondrial 12S ribosomal RNA gene mutations.^[11] Clinical studies show that the incidence of cochlear toxicity due to aminoglycoside use varies from 5 to 15% with conventional intermittent dosing of aminoglycosides.^[12]

Symptoms of ototoxicity include hearing loss, tinnitus, fullness sensation in the ear. Risk factors for cochlear damage are the age over 60 years, elevated plasma levels, preexisting ear disease, prolonged therapy, repeated doses, concomitant use of loop diuretics and other ototoxic drugs. Duration of therapy is the most important factor. In regimens lasting less than ten days toxicity is rare and if ototoxicity occurs during the first week another cause must be investigated.

Another point to be discussed in this case is whether the hearing loss was due to aminoglycoside ototoxicity and even minor doses of aminoglycosides has to be avoided. When ototoxicity is the fact, the higher dose and once-daily intravenous administration of aminoglycosides was proven to be safe due to less accumulation in the perilymph compared to traditional regimens.^[13] Ototoxicity dose range is defined as clinical and absolute ototoxicity. Clinical ototoxicity dose range causes irreversible ototoxic damage in 2% of the patients with no ototoxicity increasing factors. With the absolute ototoxicity range this risk is less than 0.2%. The clinical and absolute ototoxicity threshold doses of the modern aminoglycoside antibiotics are determined with clinical and experimental methods. For gentamicin, clinical and absolute threshold are 50 and 20 mg/kg.^[14] In our patient absolute threshold level for gentamicin was not exceeded since her body weight was 56 kg. On the other hand total and single dose administered to her was 100 mg.

SSHL is a possible complication after otologic and cardiac surgeries. The etiology is well under-

stood and established when associated with cardiac and otologic surgery.^[15] Perilymphatic fistula may cause SSHL after otologic surgery. Middle ear exploration is recommended only in cases associated with increasing hearing loss and profound vertigo.^[16]

SSHL after non-otologic non-cardiac surgery is uncommon. Although there are rare reported cases in literature exact underlying mechanisms are unknown. There are multiple etiologies proposed but there is no definitive treatment of postoperative SSHL.^[17]

This case was managed as postoperative SSHL without delay since characteristic features of aminoglycoside ototoxicity were missing. A therapeutic regimen including plasma expanders, corticosteroids, vasodilators, antivirals and hyperbaric oxygen was followed. Her hearing loss improved from profound to moderate level but further progression couldn't be achieved.

Although in idiopathic SSHL corticosteroids are shown to be effective, their effect is still unclear in postoperative SSHL associated with non-otologic non-cardiac surgery.^[18] Treatment regimens in these cases are focused to improve and maintain inner ear blood flow and oxygenation thus minimizing the cochlear disability.

Prognosis in postoperative SSHL is unclear. Severe hearing loss, down-sloping audiogram, presence of vertigo and advanced age are the unfavorable factors for recovery.^[19] Although improvement in hearing level was not satisfactory in our case, we believe that early detection and prompt evaluation of hearing loss may improve outcome inspite of the uncertainty in the etiology, the management and the prognosis.

REFERENCES

1. Byl FM Jr. Sudden hearing loss: eight years' experience and suggested prognostic table. *Laryngoscope* 1984;94:647-61.
2. de la Cruz M, Bance M. Bilateral sudden sensorineural hearing loss following non-otologic surgery. *J Laryngol Otol* 1998;112:769-71.
3. Park P, Toung JS, Smythe P, et al. Unilateral sensorineural hearing loss after spine surgery: Case report and review of the literature. *Surg Neurol* 2006;66:415-9.
4. Plasse HM, Mittleman M, Frost JO. Unilateral sudden

- hearing loss after open heart surgery: a detailed study of seven cases. *Laryngoscope* 1981;91:101-9.
5. Girardi FP, Cammisa FP Jr, Sangani PK, et al. Sudden sensorineural hearing loss after spinal surgery under general anesthesia. *J Spinal Disord* 2001;14:180-3.
6. Evan KE, Tavill MA, Goldberg AN, et al. Sudden sensorineural hearing loss after general anesthesia for nonotologic surgery. *Laryngoscope* 1997;107:747-52.
7. Segal S, Man A, Winerman I. Labyrinthine membrane rupture caused by elevated intratympanic pressure during general anesthesia. *Am J Otol* 1984;5:308-10.
8. Fee WE Jr. Aminoglycoside ototoxicity in the human. *Laryngoscope* 1980;90:1-19.
9. Hinojosa R, Lerner SA. Cochlear neural degeneration without hair cell loss in two patients with aminoglycoside ototoxicity. *J Infect Dis* 1987;156:449-55.
10. Selimoglu E. Aminoglycoside-induced ototoxicity. *Curr Pharm Des* 2007;13:119-26.
11. Prezant TR, Agapian JV, Bohlman MC, et al. Mitochondrial ribosomal RNA mutation associated with both antibiotic-induced and non-syndromic deafness. *Nat Genet* 1993;4:289-94.
12. Quintiliani Jr R, Quintiliani R, Nightingale CH. Aminoglycosides. In: Cohen J, Powderly WG, editors. *Infectious diseases*. Chapter 195. 2nd ed. Mosby Saunders; 2004.
13. Bates DE. Aminoglycoside ototoxicity. *Drugs Today (Barc)* 2003;39:277-85.
14. Federspil P. Threshold doses in ototoxicity. *HNO* 1984;32:417-8. [Abstract]
15. Walsted A, Andreassen UK, Berthelsen PG, et al. Hearing loss after cardiopulmonary bypass surgery. *Eur Arch Otorhinolaryngol* 2000;257:124-7.
16. Hughes GB, Sismanis A, House JW. Is there consensus in perilymph fistula management? *Otolaryngol Head Neck Surg* 1990;102:111-7.
17. Cox AJ 3rd, Sargent EW. Sudden sensorineural hearing loss following nonotologic, noncardiopulmonary bypass surgery. *Arch Otolaryngol Head Neck Surg* 1997;123:994-8.
18. Wilson WR, Byl FM, Laird N. The efficacy of steroids in the treatment of idiopathic sudden hearing loss. *Arch Otolaryngol* 1980;106:772-6.
19. Eisenman D, Arts HA. Effectiveness of treatment for sudden sensorineural hearing loss. *Arch Otolaryngol Head Neck Surg* 2000;126:1161-4.